

[https://doi.org/10.30702/ujcvcs/23.31\(02\)/KSS012-8588](https://doi.org/10.30702/ujcvcs/23.31(02)/KSS012-8588)
UDC 616.24-007.63

Dinesh Kumar Sathanantham^{1,2}, Postgraduate year 6 (PGY6) Resident, Department of Cardiovascular and Thoracic Surgery, Department of General Surgery, <https://orcid.org/0000-0002-7142-3348>

Spurthi Sanganbhornia², Postgraduate year 2 (PGY1) Resident, Department of General Surgery, <https://orcid.org/0000-0001-7639-1915>

Shashirekha C. A.², Assoc. Prof., Department of General Surgery, <https://orcid.org/0000-0003-3554-6268>

Sreeramulu P. N.², Prof. and HOD, Department of General Surgery, <https://orcid.org/0000-0002-9445-0891>

¹Government Medical College, Kottayam, Kerala, India

²Sri Devaraj Urs Medical College, Tamaka, Kolar, Karnataka, India

*Corresponding author.

Email address: dinesh.sathanantham@gmail.com (Dinesh Kumar Sathanantham)

Surgical Emphysema without Pneumothorax: A Diagnostic Dilemma

Abstract

Introduction. Surgical emphysema, also widely known as subcutaneous emphysema, is defined as a clinical state in which air gets trapped subcutaneously. The etiology may be traumatic or atraumatic, and multiple causes in each are present.

Case report. A 63-year-old female patient presented to the emergency room with a facial soft tissue injury following road traffic accident and developed surgical emphysema later on with no evidence of rib fractures or pneumothorax. Infectious etiology was ruled out. Due to the respiratory embarrassment, the patient was electively intubated. Conservative management was provided. Emphysema resolved within 24 hours after the accident.

Discussion. Various theories have been outlined in literature, like Mackler effect, Crampton theory and ball-valve mechanism. In our case, it was difficult to apply any of these theories to confirm the diagnosis. Conservative management is still used in the treatment of surgical emphysema.

Conclusion. Surgical emphysema is a common encounter in trauma practice, and its identification is essential to rule out any emergency causes which may lead to respiratory distress.

Keywords: *subcutaneous emphysema, Mackler effect, thoracic trauma, road traffic accident, scalp injury.*

Introduction. Surgical emphysema, also widely known as subcutaneous emphysema, is defined as a clinical state in which air is present subcutaneously. The condition was first reported in 1850 following a violent coughing fit [1]. Also, various rare causes of surgical emphysema were described: high-pressure water injury to the hand, ulcerative colitis, perforated diverticulitis and various iatrogenic causes during colonoscopy, endoscopic retrograde cholangiopancreatography, thyroidectomy, tonsillectomy, continuous positive airway pressure and ventriculo-peritoneal shunt [2].

Here we report a case of facial subcutaneous emphysema following a road traffic accident, with no evidence of fracture of ribs, air sinus or pneumothorax. Rarity of the case presented is against the effects of Mackler.

Case report. A 63-year-old female patient presented to the emergency room after road traffic accident. According to the patient's words, she was travelling in a four-wheeler and had a collision with a heavy tractor. As a result, the vehicle toppled and she fell on the road on the side of the right rear passenger's seat and got injuries to the scalp, face and hand.

On examination, the patient was conscious, oriented, with Glasgow coma scale score of 15/15 (E4V5M6). There was a laceration of 3x2 cm on the scalp in the right parietal region, abrasion of 3x2 cm on the right side of the face, abrasion of 10x3 cm in the right clavicular region and abrasion of 5x3 cm over the right knee joint, proving that the patient mainly fell on the right side; this is consistent with the history and Indian vehicles being right-hand driven. Chest compression test was negative, systemic examination yielded no abnormalities. There were no clinical signs of long bone fractures and cervical spine injuries. Facial contour was normal at the time of presentation. Adequate analgesia

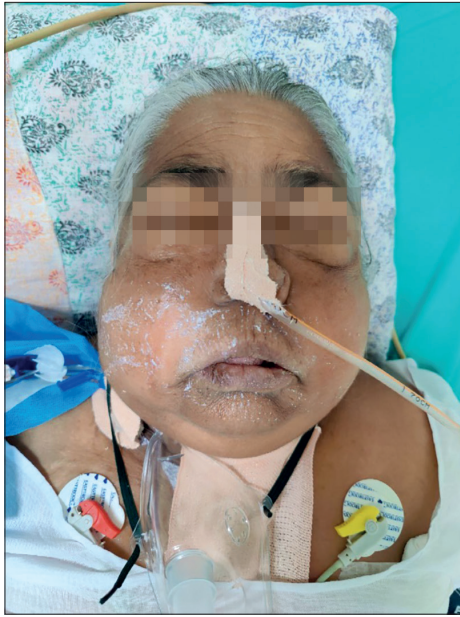

Fig. 1. Clinical photograph showing facial surgical emphysema extending from scalp to the neck region

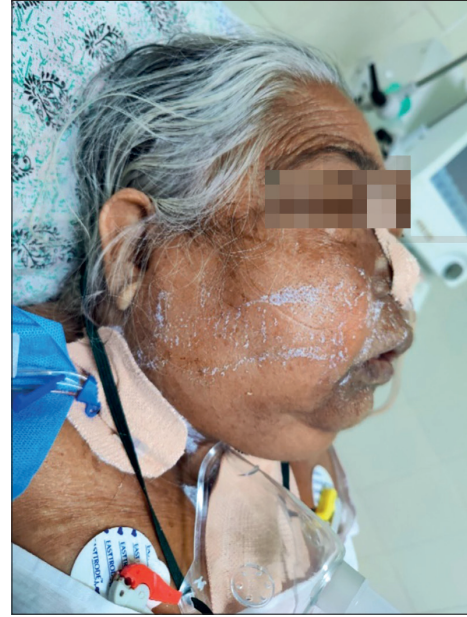

Fig. 2. Lateral photograph of the face with subcutaneous emphysema

was given; the patient underwent plain computed tomography (CT) of the brain which showed no abnormalities, facial bone/sinus fractures or parenchymal bleed.

The patient was followed up, and within one hour she developed swelling of the whole face, extending from the upper lip to the hair line (frontal) bilaterally. Crepitus and crackles were noted. The swelling progressed to involve the whole face later (Fig. 1, 2), however, it did not extend to the neck. Chest X-ray was performed to exclude pneumothorax (Fig. 3) and showed normal result. ENT consul-

tation was arranged, the doctor revealed no abnormalities and recommended conservative management. The patient was subjected to CT again, and air-filled space was noted extending from parietal region to the lower border of mandible (Fig. 4). There was no respiratory compromise or

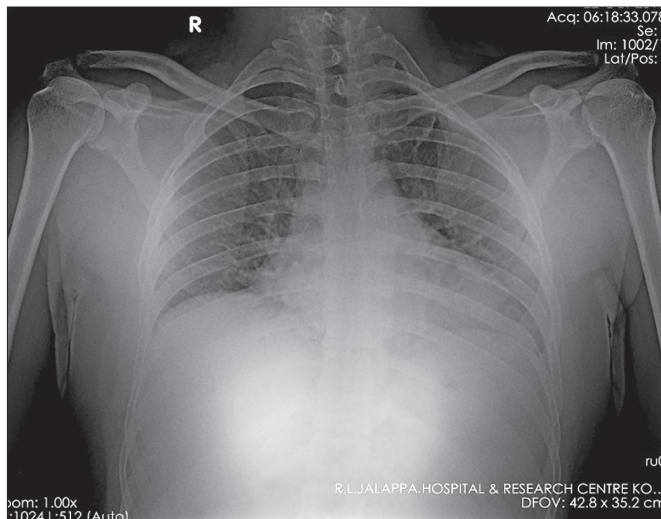


Fig. 3. Chest X-ray, posteroanterior view: no rib fractures or pneumothorax

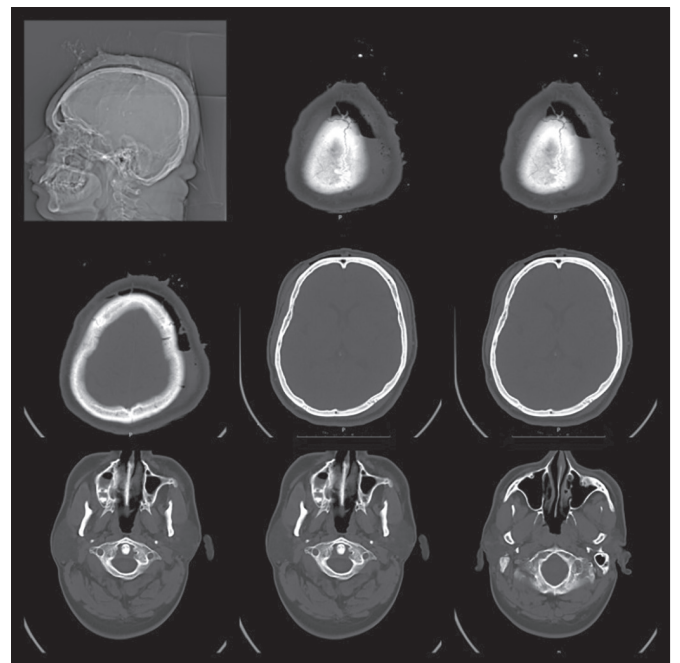


Fig. 4. CT scan showing the extent of surgical emphysema from frontal area of the skull to the level of maxilla

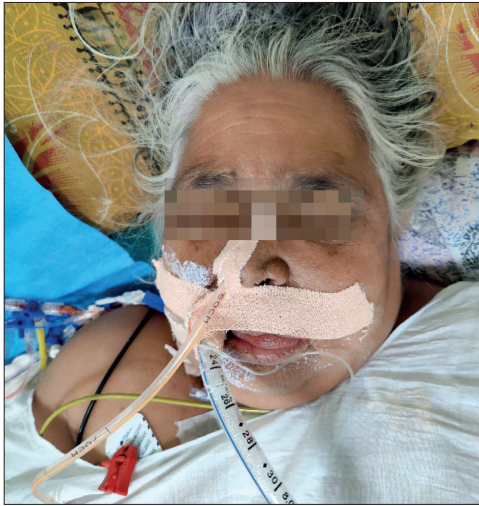

Fig. 5. Clinical photograph showing resolution of surgical emphysema

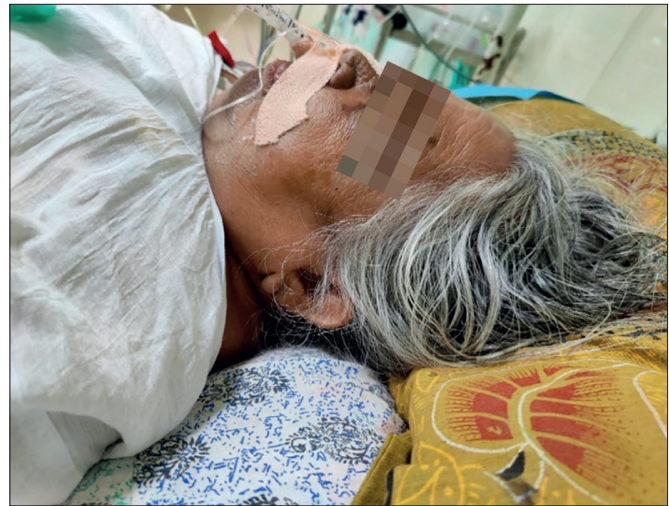

Fig. 6. Lateral view showing resolution of surgical emphysema (24 hrs after admission)

breathlessness, and saturation was at 95% at room air. In view of the increasing emphysema, trachea was electively intubated. The patient was closely observed and was kept with head-end elevation. She was transferred to surgical intensive care unit and was closely monitored.

Next day morning, resolution of the emphysema was seen, and complete resolution was observed on day 2 of admission (Fig. 5, 6). The patient was discharged, and follow-up within 1 month revealed no abnormalities and normal facial contour.

Discussion. Mackler effect of surgical emphysema following blunt trauma has been approved and accepted by many researchers. But the same effect cannot be applied in our case, since there was blunt trauma with no evidence of fracture (Fig. 3). Crampton in his paper described a 'ball-valve' mechanism provided by bandage application and mobilization during CT procedure in case of injury, and also discussed bandaging of the head over the laceration without suturing that could have caused the air to get trapped resulting in subcutaneous emphysema [3]. But the same ball-valve mechanism [4, 5] described for extremities has not been reported for the scalp till now.

One such case report states that the use of hair coloring agent acted as reaction agent leading to formation of subcutaneous emphysema of the scalp, which later on resolved spontaneously [6].

The scalp, as we know, is composed of five layers forming the acronym 'SCALP' (the skin, connective tissue, epicranial aponeurosis, loose areolar tissue, and pericranium), tightly adhered to each other, except between the loose areolar tissue and the pericranium [7]. Hence the laceration over the scalp would have been deep enough to dislodge the first 4 layers resulting in air getting trapped.

The authors' observations in this case would be the depth of laceration in the scalp which eventually resulted in dislodgement of first 4 layers, and the positioning and free movement of the patient in the trauma care unit, resulting in air insufflation. We hypothesized that a mechanism like 'trap-door' effect would have occurred, which resulted in the move of air in the scalp down up to mandible and did not let the air out. The other 4 layers of the scalp are thick, and this can confirm this hypothesis. The emphysema was observed clinically starting from the scalp and down below.

Various management plans for subcutaneous emphysema proposed by different authors are available in literature consisting of multiple stab incisions, intercostal drains, subcutaneous drains [8]. But there are no trials to prove the effectiveness of one option over the others till now. Due to the benign nature of the emphysema, the authors' recommendation is to provide careful observation, and no intervention is required for the condition as such, unless any respiratory compromise occurs. It is quite mentionable that non-infectious etiology in cases of surgical emphysema should be ruled out, as the treatment protocols differ drastically. In this case it was ruled out by culture and sensitivity tests.

Conclusion. Surgical emphysema is a benign self-limiting condition which is very common in trauma care, and necessary knowledge of it is mandatory for all surgeons, in finding out the underlying cause and taking necessary actions to avoid the progression of the condition. This case report gives a simple understanding of a complex presentation of surgical emphysema.

Conflicts of interest. The authors and co-authors declare no potential conflict of interest in research, publishing and presentation of this article.

Ethical Committee approval. Institutional Review board has given approval for the study of the case, publication and scientific presentation, vide cert. No: DMC/KLR/IEC/128/2017-18.

Scientific presentation. The case study was presented as a poster at the 36th Annual Conference of Karnataka State Chapter of the Association of Surgeons of India, February 2-4, 2018, in Hassan, Karnataka, India.

The conference does not restrict the publication of the study in any journal.

Patient consent. Obtained.

References

1. Parker GS, Mosborg DA, Foley RW, Stiernberg CM. Spontaneous cervical and mediastinal emphysema. *Laryngoscope.* 1990;100(9):938-940. <https://doi.org/10.1288/00005537-199009000-00005>
2. Aghajanzadeh M, Dehnadi A, Ebrahimi H, Fallah Karkan M, Khajeh Jahromi S, Amir Maafi A, et al Classification and Management of Subcutaneous Emphysema: a 10-Year Experience. *Indian J Surg.* 2015;77(Supl 2):673-677. <https://doi.org/10.1007/s12262-013-0975-4>
3. Venugopal K, Reddy MM, Bharathraj Y M, Kadappa J. Non-traumatic, spontaneous subcutaneous emphysema: Diagnostic and therapeutic dilemma. *Int J Health Allied Sci.* 2015;4(2):97-99.
4. De M, Stevenson J. Subcutaneous emphysema of upper limb. *Emerg Med J.* 2001;18(6):522. <https://doi.org/10.1136/emj.18.6.522>
5. Rabiul Islam SM, Mamman KG, Pande KC. Benign Subcutaneous Emphysema of the Upper Limb: A Case Report. *Malays Orthop J.* 2016;10(3):39-41. <https://doi.org/10.5704/MOJ.1611.002>
6. Tewari SO, Farouqi RM, Fuca N, Khan M, Mantello MT. Spontaneous subcutaneous emphysema of the scalp following hair coloring/treatment. *Radiol Case Rep.* 2017;12(1):78-80. <https://doi.org/10.1016/j.radcr.2016.11.007>
7. Sinnatamby CS. *Last's anatomy: regional and applied.* 12th ed. Edinburgh: Churchill Livingstone/Elsevier;2011.
8. O'Reilly P, Chen HK, Wiseman R. Management of extensive subcutaneous emphysema with a subcutaneous drain. *Respirol Case Rep.* 2013;1(2):28-30. <https://doi.org/10.1002/rcr2.9>

Підшкірна емфізема за відсутності пневмотораксу: діагностична дилема

Дінеш Кумар Сатанантам^{1,2}, аспірант-ординатор, відділення серцево-судинної і торакальної хірургії, відділення загальної хірургії

Спурті Санганбхонія², аспірант-ординатор відділення загальної хірургії

Шаширеха К. А.², доцент відділення загальної хірургії

Шрірамулу П. Н.², проф., зав. відділення загальної хірургії

¹Державний медичний коледж, Коттаям, Керала, Індія

²Медичний коледж Шрі Деварадж Урс, Тамака, Колар, Карнатака, Індія

Резюме

Вступ. Підшкірна емфізема – це клінічний стан, за якого повітря потрапляє під шкіру. Етіологія може бути травматичною або атравматичною внаслідок різних причин.

Клінічний випадок. Пацієнтка віком 63 роки потрапила до відділення невідкладної допомоги з пошкодженням м'яких тканин обличчя після дорожньо-транспортної пригоди. Пізніше в неї розвинулася підшкірна емфізема без ознак переломів ребер або пневмотораксу. Інфекційну етіологію було виключено. Через порушення дихання виконано планову інтубацію пацієнтки. Проведено консервативне лікування. Емфізема зникла через 24 години після аварії.

Обговорення. У літературі описані різні теорії, наприклад, ефект Маклера, теорія Крамптона та механізм кульового клапана. У нашому випадку важко було застосувати будь-яку з цих теорій для підтвердження діагнозу. У лікуванні хірургічної емфіземи нині застосовують консервативне лікування.

Висновок. Хірургічна емфізема є поширеним явищем у травматологічній практиці. Її ідентифікація є важливою для виключення будь-яких екстрених причин, які можуть призвести до респіраторного дистрес-синдрому.

Ключові слова: ефект Маклера, травма грудної клітки, дорожньо-транспортна пригода, пошкодження шкіри голови.

Стаття надійшла в редакцію / Received: 14.03.2023

Після доопрацювання / Revised: 04.04.2023

Прийнято до друку / Accepted: 15.06.2023