



First Experience of the Usage of Peripheral Extracorporeal Membrane Oxygenation in a Child with Severe Respiratory Insufficiency

Safonov V.¹, Sekelyk R.¹, Vysotskyi A.¹, Avetyan A.^{1,2}, Motrechko O.¹, Yemets I.^{1,2}

¹Ukrainian Children's Cardiac Center, Kyiv, Ukraine

²Shupyk National Medical Academy of Postgraduate Education, Kyiv, Ukraine

Abstract. Extracorporeal membrane oxygenation (ECMO) is a life-supporting technique in the treatment of severe cardiac and respiratory insufficiency. It is based on the prolonged extracorporeal blood circulation. Peripheral venoarterial ECMO involves withdrawing, gas exchange and returning blood through cannulas implanted in peripheral vessels.

Objective. We are interested in analysing our experience of venoarterial membrane oxygenation with peripheral cannulation, which was used in a child aged eight months with severe respiratory insufficiency after the Ross-Konno operation.

Materials and methods. The subject of this article is the patient's case with severe respiratory insufficiency in the early post-operative period because of a bacterial infection. In spite of being transferred to the artificial lung ventilation, the child's condition was worsening and the decision to use ECMO with peripheral cannulation was taken. In this particular case, there was cannulation of the right artery and right inner vein cava. Unfortunately, we had to discontinue ECMO because of a hematoma in the frontal lobe.

Results and discussion. While maintaining ECMO, we managed to improve the patient's condition and make it stable, evidenced by the laboratory and instrumental tests. This case is indicative of the possibility of using ECMO with peripheral cannulation in infants with severe respiratory insufficiency.

Conclusions. ECMO is quite an effective method of treatment of severe respiratory insufficiency, which allows creating favourable conditions to overcome the infection and renew the pulmonary function. As compared with the central technique, the peripheral ECMO ensures sufficient gas-exchange even using cannulas of a smaller diameter. Peripheral cannulation is the efficacious way to avoid complications occurring during the central cannulation. The complications that occurred during venoarterial ECMO were reversible and not associated with cannulation.

Keywords: *extracorporeal membrane oxygenation, peripheral cannulation, severe respiratory insufficiency.*

Extracorporeal membrane oxygenation (ECMO) is an important method in the treatment of severe cardiac and respiratory insufficiency [1]. According to the 2018 Extracorporeal Life Support Organisation Registry, since the first publication of the successful use of ECMO in 1972 in adults and in 1974 in children under one year of age, over 100,000 cases of ECMO have been reported 43,000 of which in children [2-4]. Extracorporeal membrane oxygenation is a life-supporting technique based on prolonged artificial circulation [1]. The peripheral venoarterial ECMO technique consists of sampling, gas exchange and return of blood through the cannulas installed in the peripheral vessels [5]. In our case, the right common carotid artery and the right internal jugular vein were cannulated.

The objective of the work is to analyse our experience of venoarterial membrane oxygenation with peripheral cannulation, which was used in a child with severe respiratory insufficiency after the Ross-Konno operation.

Materials and methods

A child aged 7 months, weighing 6.5 kg, was admitted to the Ukrainian Children's Cardiac Center, with the diagnosis of combined aortic valve disease with the prevalence of insufficiency, severe left ventricular systolic dysfunction, left ventricular endocardial fibroelastosis. Patient underwent aortic valve balloon dilatation at the age of 1 day old and aortic valve repair at the age of 1 month. Echocardiography showed the left ventricular ejection fraction (LV EF) 20%, the left ventricular end-diastolic index (LV EDI) was 219.6 ml/m². In addition, severe aortic insufficiency with the maximum aortic valve gradient of 66 mmHg were identified. The patient underwent routine Ross-Konno procedure, the postoperative course was uneventful. Given severity of initial condition, the patient received following inotropic support immediately after stopping the heart-lung machine: dopamine 5 µg/kg/min, dobutamine 5 µg/kg/min, adrenaline 0.005 µg/kg/min and levosimendan 0.2 µg/kg/min. The sternum was left open for 2 days. On Day 7 after the operation, the patient was extubated, with recovered the left ventricular ejection fraction and it was possible to decrease for the first time and then completely discontinue inotropic support. On Day 9, the patient was intubated and switched to artificial lung ventilation (ALV) with the progression of respiratory failure and deterioration of the leukocyte formula. The parameters of the complete blood count were: leukocytes – 14.7x10⁹/l; eosinophils – 0%; stabs – 24%; segmented – 62%; lymphocytes – 10%; monocytes – 4%. On Day 12, with the rapid progression of hypoxemia and hypercapnia, the patient was transferred to high-frequency ventilation (HFV), but the parameters of the gas composition of the arterial blood were deteriorating. With the fractional concentration of oxygen in 100% respiratory mixture they were: hydrogen

index (pH) – 7.23; partial pressure of carbon dioxide in arterial blood (pCO₂) – 75.6 mmHg; partial pressure of oxygen in arterial blood (pO₂) – 40.9 mmHg; the saturation of arterial blood with oxygen (SaO₂) – 69%. There was also negative changes of the leukocyte formula parameters: leukocytes 11.9x10⁹/l; eosinophils – 2%; stabs – 37%; segmented – 53%; lymphocytes – 5%; monocytes – 2%. Bacterioscopic examination of the sputum from the upper respiratory tract upon preliminary microscopy detected *Klebsiella pneumoniae* and *Stenotrophomonas maltophilia*.

On Day 13 after surgery, it was decided to connect venoarterial ECMO with peripheral cannulation through the right common carotid artery and right internal jugular vein. A transverse skin incision was performed over the right clavicle in the region of the sternocleidomastoid muscle to access the right neurovascular bundle of the neck. The right common carotid artery and the internal jugular vein were mobilized and bandaged in the distal part. The right common carotid artery was cannulated proximally with a straight reinforced cannula of 3.3 mm in diameter and a right internal jugular vein was cannulated with a straight reinforced cannula of 4 mm in diameter, and an extracorporeal membrane oxygenation machine was connected. The cannulas were fixed twice to the tourniquets on the vessels and to the skin, the skin over the cannulation site was sutured to avoid local infectious complications [6]. On Day 6 of ECMO, the circuit was replaced.

During routine neurosonography, on Day 11, a focal of increased echogenicity was detected, probably a hematoma, 20 mm in diameter on the left in the upper frontal lobe, located periventricularly without connection to the ventricular cavity. Subsequently, the hematoma in the frontal lobe increased on the left side during the day, so ECMO was stopped and decannulation were performed.

Venoarterial ECMO was accompanied with constant monitoring of coagulation parameters, blood gas composition, complete blood count, blood biochemistry, monitoring of cerebral pulse oximetry, echocardiography and neurosonography. The patient received antibacterial therapy based on the culture during the entire stay in the ICU. Cefuroxime sodium, meropenem trihydrate, colistimethate sodium, phosphomycin sodium, sulfamethoxazole and trimethoprim were prescribed.

Results and discussion

While maintaining ECMO, we managed to improve the patient's condition and make it stable, evidenced by the laboratory and instrumental tests. On Day 12 of ECMO, it was decided to stop it and transfer the patient to HFV due to the hematoma in the frontal lobe on the left. The patient was on HFV for 41 days, after which he was transferred to traditional ventilation, which lasted next 26 days and

allowed transferring the patient to spontaneous breathing. The patient was in the ward of the cardiac surgery unit for 15 days and was discharged home in a satisfactory condition on Day 107 after surgery.

Upon discharge, the child's neurological status was assessed by a neurologist. The child was conscious, reacted with a quiet cry, the photoreactions were brisk, the child did not fix the eyes on the toy, sensorineural hearing loss, left-sided central hemiparesis were observed. According to the literature, the incidence of intracranial haemorrhages following ECMO is 19% [7]. The most common causes of intracranial haemorrhage is anticoagulation therapy during extra-corporal membrane oxygenation [8]. Given the nature and localization of brain damage, the hematoma in the frontal lobe on the left is not associated with the method of peripheral cannulation with contralateral ligation of the neck vessels [9].

3 months after surgery, computed tomography with reconstruction of the vessels was performed, which showed complete obliteration of the right neurovascular bundle of the neck with compensatory enlargement of collateral vessels (Fig. 1). The neurological status was re-evaluated by a neurologist after 7 months. Upon examination, the child was conscious, responded to the examination with motor activity. Hearing and visual acuity were somewhat reduced, the gaze was fixed, the child followed the toy well, reached for and held it. There was convergent strabismus due to the left eye. The face was symmetrical. The muscle tone was reduced, mainly in the feet. There was mild left central hemiparesis. The baby rolled from tummy to back.

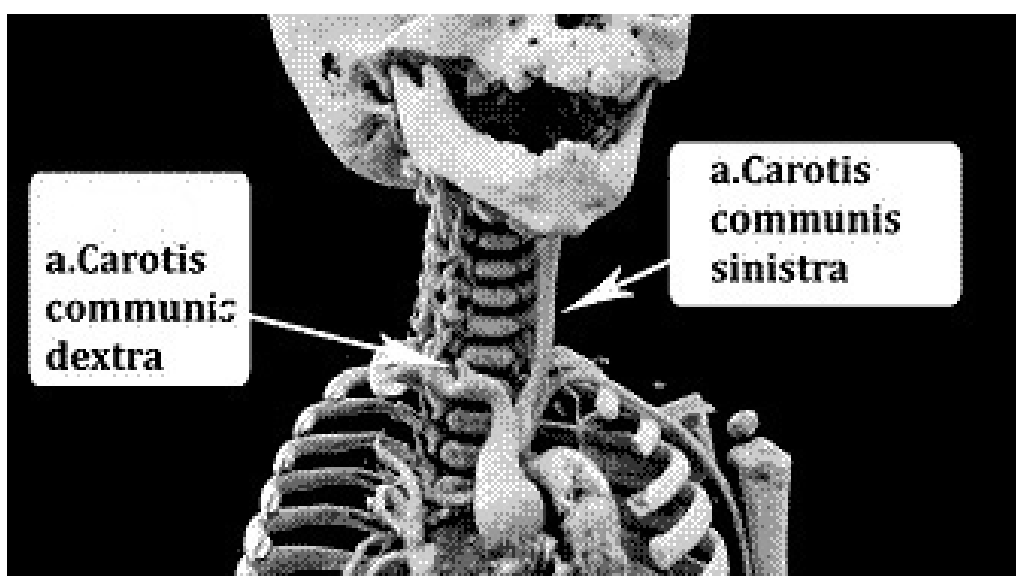


Fig. 1. Computed tomography of the neck vessels with 3D reconstruction

According to the data of echocardiography performed in 7 months, LV EF was 68%, LV EDI was 63.26 ml/m². The maximum pressure gradient on the aortic valve was 4 mm Hg. There was mild stenosis of the conduit of the pulmonary artery with the maximum gradient of 24 mm Hg. Mild insufficiency of the mitral valve. Residual mild left ventricular hypertrophy.

The described case is the confirmation that ECMO with peripheral cannulation can be used in children of the first year of life with severe respiratory failure [1–3, 10]. The advantages of this technique include less tissue trauma during cannulation and decannulation and the possibility of performing the procedure in the intensive care unit, the absence of the risk of damage to the mediastinum, especially in children with the surgery in anamnesis [1, 5, 6, 10-12]. When using this technique, there is less likelihood of developing infectious complications, intra-operative and postoperative blood loss, as well as faster activation of the patient after disconnection from the extracorporeal membrane oxygenation apparatus [3, 5, 6, 10-12].

Conclusions

- ECMO is quite an effective method of treatment of severe respiratory insufficiency, which allows creating favourable conditions to overcome the infection and restore the pulmonary function.
- In comparison with the central technique, the peripheral ECMO ensures sufficient gas-exchange even using cannulas of a smaller diameter.
- Peripheral cannulation is the efficacious way to avoid complications occurring during the central cannulation.
- The complications that occurred during venoatrial ECMO were not associated with cannulation and reversible upon assessing the neurological status in dynamics.

References

1. Bahrami KR, Van Meurs KP. ECMO for neonatal respiratory failure. *Seminars in perinatology*. 2005;29:15–23.
2. Hill JD, O'Brien TG, Murray JJ, Dontigny L, Bramson ML, Osborn JJ, Gerbode F. Prolonged extracorporeal oxygenation for acute post-traumatic respiratory failure (shock-lung syndrome): use of the Bramson membrane lung. *N Engl J Med*. 1972;286(12):629–34.
3. Bennett CC, Johnson A, Field DJ, Elbourne D; UK Collaborative ECMO Trial Group. UK collaborative randomised trial of neonatal extracorporeal membrane

- oxygenation: follow-up to age 4 years. *Lancet*. 2001;357(9262):1094–6. [https://doi.org/10.1016/S0140-6736\(00\)04310-5](https://doi.org/10.1016/S0140-6736(00)04310-5)
4. Extracorporeal Life Support Organization [Internet]. Michigan; c2019 [cited 2019 Jan 30]. Extracorporeal Life Support Registry Report; [about 1 screen]. Available from: <https://www.elseo.org/Registry/Statistics/InternationalSummary.aspx>
 5. Pavlushkov E, Berman M, Valchanov K. Cannulation techniques for extracorporeal life support. *Ann Trans Med*. 2017;5(4):70. <https://doi.org/10.21037/atm.2016.11.47>
 6. Extracorporeal Life Support Organization [Internet]. Michigan; c2019. Extracorporeal life support organization (ELSO guidelines); [about 1 screen]. Available from: <http://www.elseo.org/resources/Guidelines.aspx>
 7. Bulas DI, Taylor GA, O'Donnell RM, Short BL, Fitz CR, Vezina G. Intracranial abnormalities in infants treated with extracorporeal membrane oxygenation: update on sonographic and CT findings. *AJNR Am J Neuroradiol*. 1996;17(2):287–94.
 8. Dela Cruz TV, Stewart DL, Winston SJ, Weatherman KS, Phelps JL, Mendoza JC. Risk factors for intracranial hemorrhage in the extracorporeal membrane oxygenation patient. *J Perinatol*. 1997;17(1):18–23.
 9. van Heijst AF, de Mol AC, Ijsselstijn H. ECMO in neonates: neuroimaging findings and outcome. *Semin Perinatol*. 2014;38(2):104–13. <https://doi.org/10.1053/j.semperi.2013.11.008>
 10. Prodhon P, Stroud M, El-Hassan N, Peeples S, Rycus P, Brogan TV, et al. Prolonged extracorporeal membrane oxygenator support among neonates with acute respiratory failure: a review of the Extracorporeal Life Support Organization registry. *ASAIO J*. 2014;60(1):63–9. <https://doi.org/10.1097/MAT.0000000000000006>
 11. Reeb J, Olland A, Renaud S, Lejay A, Santelmo N, Massard G, et al. Vascular access for extracorporeal life support: tips and tricks. *J Thorac Dis*. 2016;8(Suppl4):S353–63. <https://doi.org/10.21037/jtd.2016.04.42>
 12. Makdisi G, Wang IW. Extra corporeal membrane oxygenation (ECMO) review of a lifesaving technology. *J Thorac Dis*. 2015;7:E166–76. <https://doi.org/10.3978/j.issn.2072-1439.2015.07.17>